

# Intraoral Approach and Stereolithographic-guided Large Mandibular Reconstruction with Fibula Free Flap

Artur Diaz-Carandell, MD\*  
 Eugenia Agut-Busquet, MD†  
 Juan Molina-Montes, MD,  
 DDS\*  
 Oscar Escuder-LaTorre, MD\*

**Summary:** The reconstruction of mandibular defects has always been of great concern, and it still represents a challenge for head-and-neck reconstructive surgeons. The mandible plays a major role in mastication, articulation, swallowing, respiration, and facial contour. Thus, when undertaking mandibular reconstruction, restoration of both function and cosmetics should be considered as the measure of success. Microsurgical reconstruction is the gold-standard method to repair a segmental mandibular defect. Reconstruction of sizeable defects often needs a large neck incision, leading to unsatisfactory cosmetic outcomes. Virtual surgical planning and stereolithographic modeling are new techniques that offer excellent results and can provide precise data for mandibular reconstruction and improve postoperative outcomes. We present a case of complete intraoral resection and reconstruction of a large ameloblastoma of the mandible. (*Plast Reconstr Surg Glob Open* 2014;2:e199; doi: 10.1097/GOX.000000000000162; Published online 12 August 2014.)

## CASE REPORT

A 27-year-old man with no history of health conditions complained of a fast-growing, painless mass on the right side of the mandible. Orthopantomography and computed tomography (CT scan) showed an expansive multilocular 7-cm lesion located in the right mandibular angle, extending downward to the mandibular canal and upward to the right mandibular ramus (Fig. 1).

Anatomopathological findings in the biopsy performed lead to the diagnosis of ameloblastoma.<sup>1</sup>

From the \*Oral and Maxillofacial Department, Hospital Parc Tauli, Sabadell, Barcelona, Spain; and †Department of Dermatology, Hospital Parc Tauli, Sabadell, Barcelona, Spain. Received for publication March 7, 2014; accepted June 25, 2014.

Copyright © 2014 The Authors. Published by Lippincott Williams & Wilkins on behalf of The American Society of Plastic Surgeons. *PRSGO* is a publication of the American Society of Plastic Surgeons. This is an open-access article distributed under the terms of the Creative Commons Attribution-NonCommercial-NoDerivatives 3.0 License, where it is permissible to download and share the work provided it is properly cited. The work cannot be changed in any way or used commercially.

DOI: 10.1097/GOX.000000000000162

A CT scan was used to create a stereolithographic model of the mandible. Preplating was carried out preoperatively.

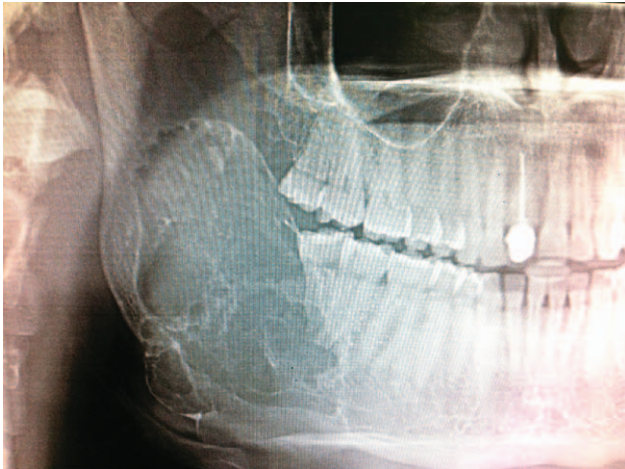
Under general anesthetics, the patient underwent surgery via an intraoral approach. The buccal, labial, and lingual flaps were harvested, and the entire right hemimandible was exposed. The temporal tendon insertion was detached from the coronoid process. The mucosa was completely preserved.

Segmental mandibulectomy from tooth 45 to sigmoid notch was carried out. With cautious subperiosteal dissection, the surgical piece, including the tumor and its margins (measuring: 9×5, 5×2 cm), was entirely removed intraorally (Fig. 2).

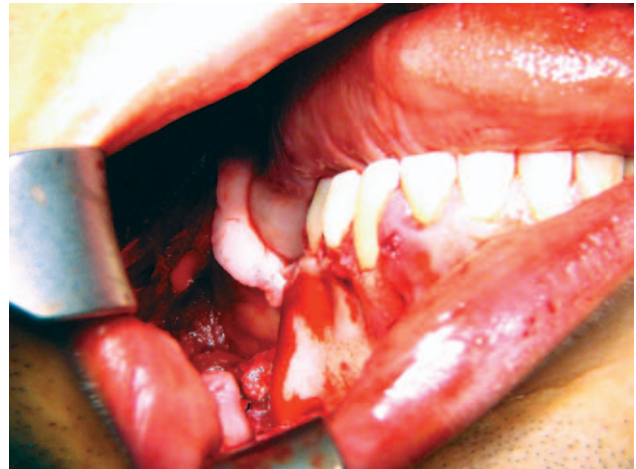Through a submandibular 2-cm incision, the facial artery and vein were prepared as recipient vessels. Through this incision, a channel to the oral cavity was created.

Simultaneously, a second team harvested the osteocutaneous fibula free flap from the left leg with a 2×4-cm skin paddle, based on a perforator artery

**Disclosure:** The authors have no financial interest to declare in relation to the content of this article. The Article Processing Charge was paid for by the authors.



**Fig. 1.** Preoperative orthopantomography.



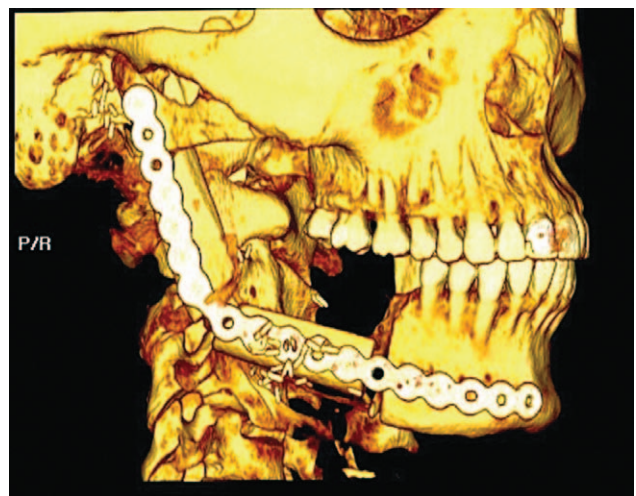
**Fig. 2.** Complete intraoral excision.

and then used as an intraoral monitor. The bone was fixed to the premodeled plate with monocortical screws before devascularization from the leg was performed. The flap was formerly transplanted into the defect. The vertical discrepancy between the fibula and the patient's remaining healthy mandible was corrected, and the flap was then fixed to it with bicortical screws, using a modified (shortened) Al-Kayat's incision to approach the temporomandibular joint.

Anastomoses through the submandibular incision were reached. The intraoral mucosa and submandibular and preauricular incisions were closed with direct sutures. The donor site was closed with direct suture and a split-thickness skin graft from the inner thigh. The patient was discharged 6 days later, with no complications. A CT scan was performed 8 months after surgery (Fig. 3). Ten months later, the patient's functional recovery was positive in addition to an absolute final esthetic outcome (Fig. 4).


### DISCUSSION

The traditional surgical approach for resection of mandibular benign tumors or large lesions, via either mandibulotomy or mandibulectomy, is an extraoral approach, which is associated with significant functional and esthetic sequelae.<sup>2</sup> Such an approach leaves the patient with a scar on the skin of the submandibular and submental areas and, in some cases, the mental and lip areas. Therefore, it does not fulfill one of the important criteria for adequate reconstruction<sup>3</sup> as stated by Myers<sup>4</sup>: "Secondary cosmetic deformities should be avoided unless no other alternative is satisfactory in the situation." Keeping this objective in mind and in view of the patient's long-term prognosis, the type of defect, and resultant donor-site morbidity, it is important for the surgeon to be familiar with a wide range of reconstructive al-



**Fig. 3.** CT scan 8 months after surgery.

ternatives so that the best procedure for each patient can be chosen. Microvascular free tissue transfer has become the preferred method for mandibular reconstruction since Hidalgo<sup>5</sup> performed the first case in 1986. To reach better functional outcomes and minimize esthetic sequelae, mandibular reconstruction via an intraoral approach must be taken into account because it avoids facial incisions, preserves the perioral musculature, and reduces distress.<sup>6</sup> In upper defects involving the superior part of the mandibular ramus, as in the case of our patient, a modified (shortened) Al-Kayat's preauricular incision may be necessary to reach the condyle area and ensure subcondylar adequate fixation and congruence of the graft to the native mandible. Various authors in different surgical procedures have already described variations of such an incision. In 2008, Biglioli and Colletti<sup>7</sup> also described a limited retromandibular incision to approach condylar fractures, drawing as



**Fig. 4.** Postoperative outcomes 10 months after surgery.

a result satisfactory management of the fracture and reduction of facial nerve injury rates. In 2004, in the XVII European Congress for Craniomaxillofacial Surgery, Devauchelle et al<sup>8</sup> presented a short study of 3 cases of mandibular resection using a simultaneous intraoral and face-lift approach. In 2 of the patients, reconstruction was performed using a fibular free flap, whereas in the third patient, reconstruction was carried out using an iliac free flap. In 2 of the cases, the necessity to approach the mandibular condyle warranted the dissection of the facial nerve. Devauchelle et al<sup>8</sup> emphasizes that a minimally invasive approach is very significant, not only for esthetic reasons but also for psychological ones. Most recently, García-Diez<sup>9</sup> described a rhytidectomy approach for mandibular reconstruction with microvascular free flaps through the parotid gland, with the subsequent risk of facial nerve injury.

### CONCLUSIONS

Although some studies have been published about intraoral resection of ameloblastomas<sup>10</sup> followed by partial intraoral reconstruction, as far as we know, neither reports have been published of adults about complete intraoral resection of large posterior mandibular lesions nor has immediate intraoral mi-

crovascular reconstruction using a stereolithographic model with such small incisions as ours ever been performed.

With this report, we seek, first, to confirm that an intraoral approach and preoperative modeling of the titanium plate using a stereolithographic model shortens surgery and leads to better results<sup>11</sup> and, second, to document the feasibility of mandibular reconstruction carried out using fibular free flap even in upper subcondylar defects.

*Artur Diaz-Carandell, MD*

Hospital Parc Tauli, Sabadell

Barcelona, Spain

E-mail: adiazcarandell@gmail.com

### PATIENT CONSENT

*The patient provided written consent for the use of his image.*

### REFERENCES

1. Reichart PA, Philipsen HP, Sonner S. Ameloblastoma: biological profile of 3677 cases. *Eur J Cancer B Oral Oncol.* 1995;31B:86–99.
2. Farwell DG, Futran ND. Oromandibular reconstruction. *Facial Plast Surg.* 2000;16:115–126.
3. Neligan PC, Wei F-C. *Microsurgical Reconstruction of the Head and Neck.* St. Louis, MI: Saunders Elsevier; 2009.
4. Myers EN. Reconstruction of the oral cavity. *Otolaryngol Clin North Am* 1972;5:413.
5. Hidalgo DA. Fibula free flap: a new method of mandible reconstruction. *Plast Reconstr Surg.* 1989;84:71–79.
6. Givol N, Chaushu G, Yafe B, et al. Resection of the anterior mandible and reconstruction with a microvascular graft via an intraoral approach: a report of two cases. *J Oral Maxillofac Surg.* 1998;56:792–796.
7. Biglioli F, Colletti G. Mini-retromandibular approach to condylar fractures. *J Craniomaxillofac Surg.* 2008;36:378–383.
8. Devauchelle B, D'Hauthuille C, Testelin S, et al. Microsurgical reconstruction of the mandible through rhytidectomy approach. In: *Paper Presented at XVII European Congress for Craniomaxillofacial Surgery.* Tours, France; September 14–18, 2004.
9. García-Diez EM, Cho-Lee GY, Raigosa-García JM, et al. Rhytidectomy approach for mandibular reconstruction with microvascular free flaps after resection of mandibular benign tumors. *J Oral Maxillofac Surg.* 2013;71:2156–2168.
10. Bianchi B, Ferri A, Ferrari S, et al. Subtotal mandibular reconstruction using an intraoral approach: report of 2 cases. *J Oral Maxillofac Surg.* 2008;66:2654–2656.
11. Wang WH, Zhu J, Deng JY, et al. Three-dimensional virtual technology in reconstruction of mandibular defect including condyle using double-barrel vascularized fibula flap. *J Craniomaxillofac Surg.* 2013;41:417–422.